



الجامعة السورية الخاصة
SYRIAN PRIVATE UNIVERSITY

Dr. Nazir Ibrahim

MRCP, Hepatology & Gastroenterology

Associate professor

Second lecture 2019 -2020

hepatitis A

No chronic infection

Hepatitis A

Hepatitis A		
Virus		
Nucleic acid	RNA	RNA
Size (diameter)	27 nm	27 nm
Incubation	2-4 w	3-8 w
Spread		
Faeces	Yes	Yes
Blood	Uncommon	No
Saliva	Yes	?
Sexual	Uncommon	?
Vertical	No	No
Prevention		
Active	Vaccine	No
Passive	Immune serum globulin	No

	Hepatitis B	Hepatitis C	Hepatitis D
Virus			
Nucleic acid	<u>DNA</u>	RNA	RNA
Size (diameter)	42 nm	30-38 nm	35 nm
Incubation	4-20 w	2-26 w	6-9 w
Spread			
Faeces	No	No	No
Blood	Yes	Yes	Yes
Saliva	Yes	Yes	?
Sexual	Yes	Uncommon	Yes
Vertical	Yes	Uncommon	Yes
Chronic infection	Yes	Yes	Yes
Prevention			
Active	Vaccine	No	Prevented by
Passive	Hyperimmune globulin	No	<u>hepatitis B vaccine</u>

Acute hepatitis

Acute viral hepatitis(A, B, C, D ,E)

- Drugs induced hepatitis
- Alcoholic acute hepatitis
- Toxic hepatitis

COMPLICATIONS OF ACUTE VIRAL HEPATITIS

- Acute liver failure
- Cholestatic hepatitis
- Aplastic anaemia
- Chronic liver disease and cirrhosis (B and C)
- Relapsing hepatitis

Managmemnt

Sedatives and narcotics, should be avoided.

No specific dietary modifications are needed

Elective surgery should be avoided

HAV

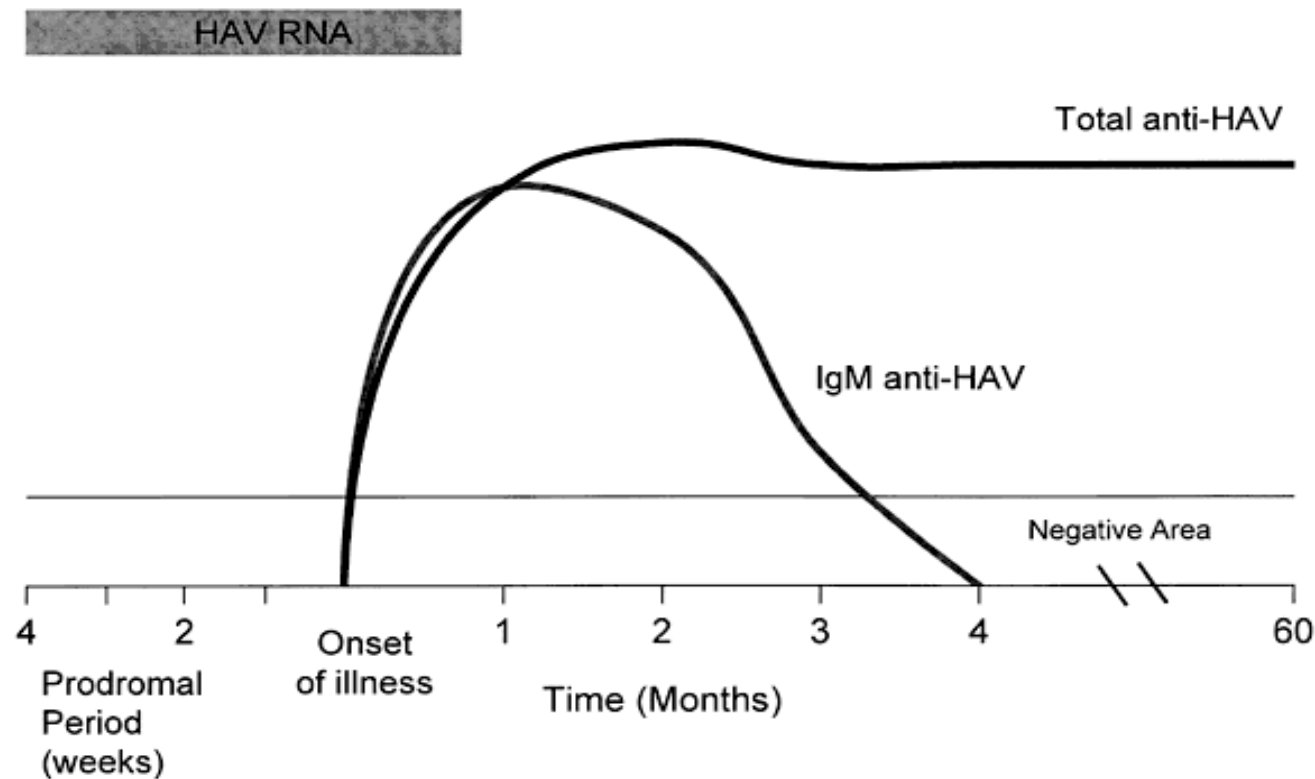
- excrete the virus in faeces for about
- 2-3 weeks before symptoms
- 2 weeks after
- May be asymptomatic, so up to 30% of adults will have serological evidence of past infection but give no history of jaundice.
- In occasional outbreaks water and shellfish have been the vehicles of transmission

Anti-HAV

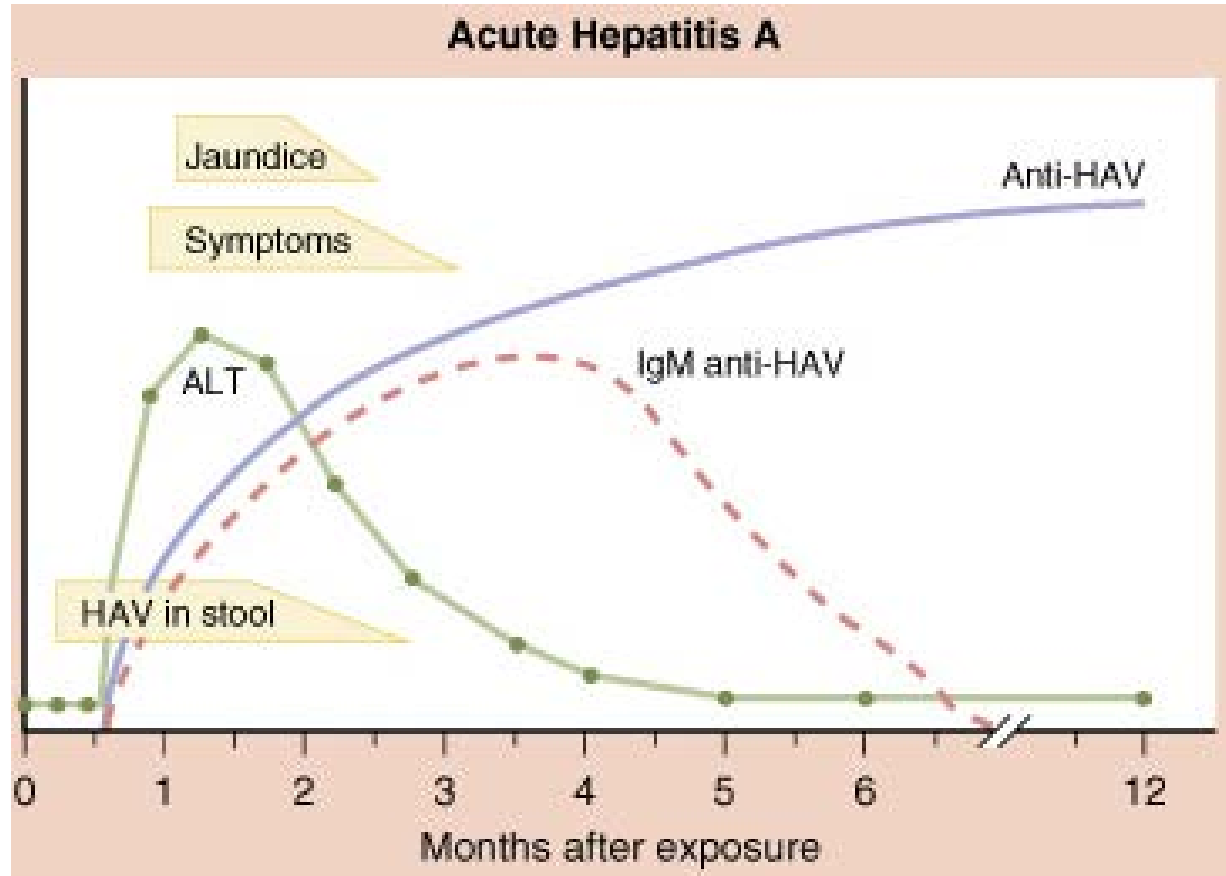
HAV is only present in the blood transiently during the incubation period. the virus cannot be grown readily.

Anti-HAV of IgM type, is already present in the blood at the onset of the clinical illness and is diagnostic of an acute HAV infection.

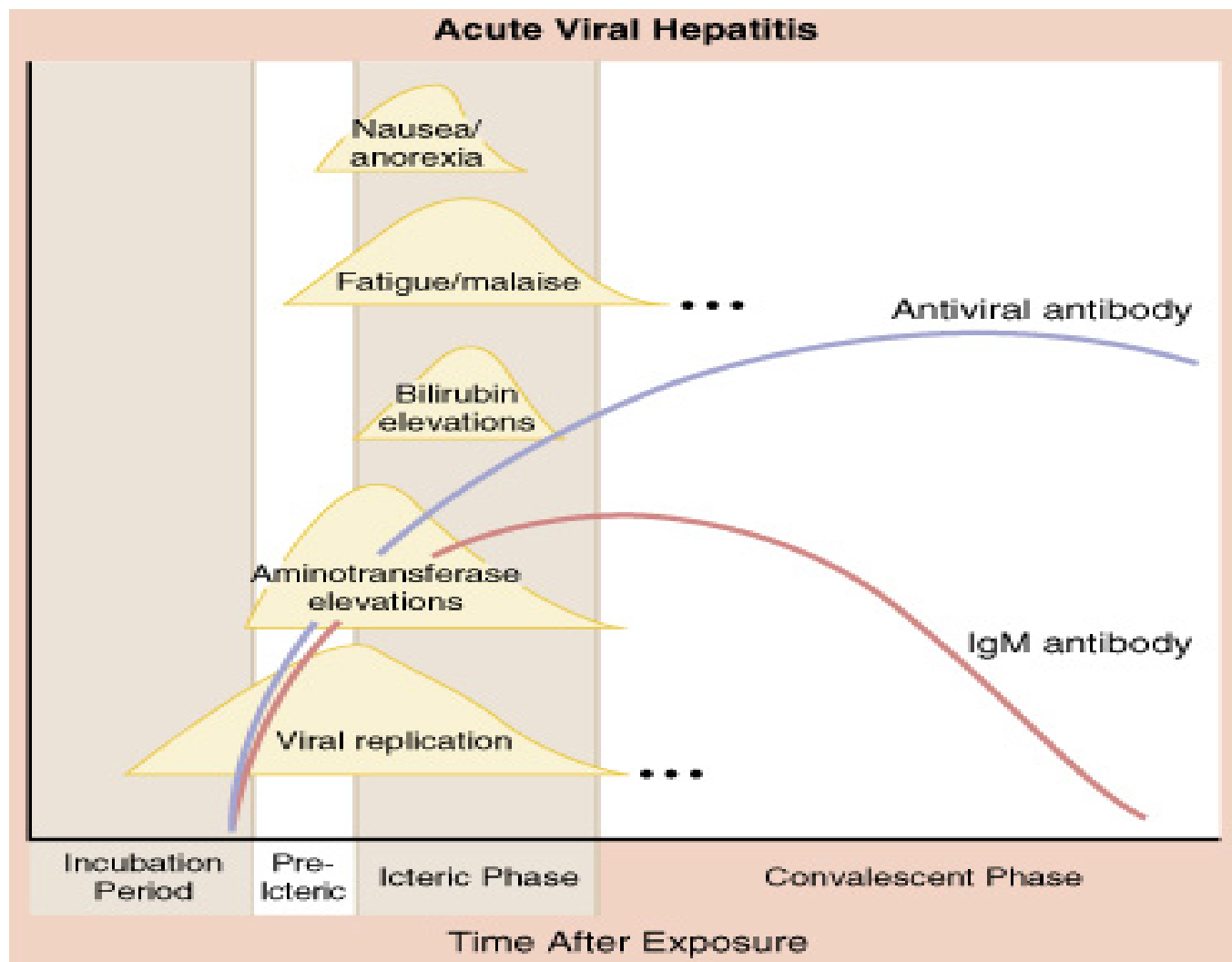
الاختبارات المصلية لالتهاب الكبد الفيروس الحاد A



الاختبارات المصلية لالتهاب الكبد الفيروسي الحاد أ



الشكل السريري الوصفي لالتهاب الكبد الفيروسي الحاد



Investigation

Anti-HAV

HAV Blood

HAV stool

Anti-HAV of IgM type

diagnostic of an acute HAV infection.

Investigation

Diagnostic of an acute HAV infection

Anti-HAV of IgM type

Anti-HAV of IgG type

is of no diagnostic value

-it can be used to measure the prevalence of HAV infection.

Its presence indicates immunity to HAV

Prognosis

- Acute liver failure complicates acute hepatitis A in only 0.1% of cases
- chronic infection does not occur.
- However, HAV infection in patients with chronic liver disease may be life-threatening disease.

Immunization HAV

should be considered for individuals with

-chronic hepatitis B or C infections.

-particular risk such as

1-close contacts

2- Elderly

3-Those with other major disease

4- ?pregnant women

5- People travelling to endemic areas

THANK YOU FOR YOUR TIME .

www.spu.edu.sy